

# ROOT CANAL TREATMENT

by Dr David Howard  
THE ALTERNATIVE VIEW

The subject of root canal treatment is one of the most challenging for holistic dentists and patients. The amalgam/mercury issue, by comparison, is neatly solved by proper amalgam removal procedures and mercury detoxification. Not only do the replacement tooth-coloured fillings look better, but most people also notice an improvement in their wellbeing.

The root canal issue is a different one, and more difficult emotionally. The ideal treatment for most people with a dead tooth or infected root canal is extraction — if health is the main concern. Replacements are usually possible but often expensive. Therefore the holistic approach to dead teeth has a much higher emotional and financial price than the conventional one.

Diagram A shows the anatomy of a tooth. Diagram B shows a tooth that has become diseased. The most common cause of tooth disease is deep tooth decay that allows bacteria to reach into the pulp. The pulp may then become inflamed or infected. Once exposed, the dental pulp has limited ability to fight infection. Products of infection may then spread into the surrounding bone and an abscess can result. From time to time, the infection will become acute and give pain, but such infections can be chronic but relatively painless most of the time. Other causes of pulp damage include traumatic blows to teeth, loose fillings, excessive wear of teeth, cracked teeth and gum disease. These can also lead to infection of the pulp.

Put simply, root canal therapy is the conventional treatment for a dead or abscessed tooth. The treatment involves cleaning the infected pulp, disinfecting the area and sealing the cavity. In most cases, the tooth will settle and be pain free. Unfortunately, it's not possible to

completely clean the infected pulp. This is mainly because there are millions of tubules in the pulp that cannot be accessed by cleaning instrumentation or disinfection. These tubules are the size of eight bacteria wide and a front tooth has approximately four kilometres of them, so they can never be completely sterilised.

When you have a dead or root-filled tooth, therefore, you have all these bacteria inhabiting the tubule in an oxygen-deficient environment, as there is now no blood supply and no connection with the immune system. The bacteria slowly morph into gram-negative anaerobic bacteria. Anaerobes have a metabolism independent of

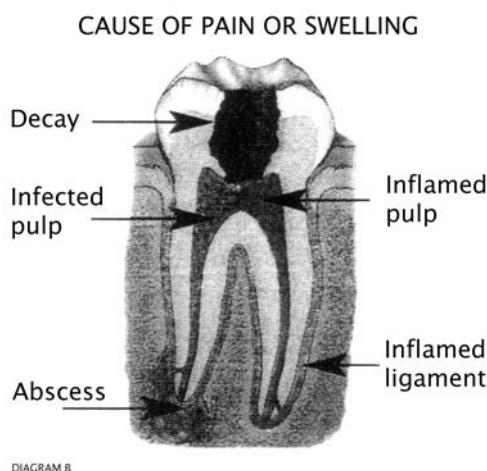
oxygen; in fact, oxygen quickly kills most of them. Anaerobes produce toxins, the best-known of which is endotoxin. Other well-known gram-negative anaerobes include the species that cause gangrene, meningococcal disease and botulism.

The toxins readily diffuse out of the tooth into the ligament and then into the body. Nutrient-containing fluids diffuse the other way, back into the tooth, thus the bacteria continue to thrive. The toxin can create tissue damage, coagulation and inflammation in other tissues. Additionally, the materials used to fill the root include bismuth oxide, silver, methamine, zinc oxide and formaldehyde. Many these canal-filling materials are toxic or allergenic in themselves, or in

combination with the denatured protein remnants of the dead tooth.

## Neural focal interference

Another reason root canal therapy can create health problems is neural focal interference. Neural therapy is a treatment approach that postulates that an electrical or neural “focus” generating small



## Endotoxin

Endotoxin is probably the most significant byproduct of dead teeth. It is a complex lipopolysaccharide that is a structural part of the cell wall of gram-negative bacteria. It is also heat-stable, so even if it were possible to kill the bacteria in the dentine tubules, their endotoxin is still bioavailable. Endotoxin is the most potent known exogenous activator of the coagulation system. It also activates the "complement cascade", a system of at least 15 proteins that play a role in immunity and inflammation. Endotoxin can convert the normally beneficial coagulation system into a pathological cascade.

Endotoxin kill at least 300,000 Americans per year as a direct result of the release of these chemicals into the blood of patients with septicaemia (blood poisoning). It's now thought that the major symptoms of meningococcal disease are due to the endotoxin released by the meningococcal bacteria. Endotoxin is also associated with myriad diseases and syndromes including organ-specific diseases such as cystic fibrosis, inflammatory bowel disease, liver disease, kidney dialysis complications, asthma and autoimmune diseases.

In gum disease, for example, gram-negative bacteria and endotoxin can accumulate on the tooth surface, penetrate into the gum and enter circulation. The local response is soft tissue loss and bone destruction. Current research shows that people with gum disease have a significantly increased risk of cardiovascular disease, presumably through vascular inflammation triggered by the gram-negative bacteria entering the blood from the gum. The precise role of endotoxin is unclear in this case but is considered the most fruitful direction of research.

It has been known for a long time that endotoxin leaks from dead teeth. The new research shows how continual small amounts leaching from such teeth can then set up a variety of diseases, often of the inflammatory or autoimmune kind, at a distance from the tooth. It is speculated that the organs or structures affected are weakened by genetic or other factors. Autoimmunity is where the immune system is triggered to attack the body's own cells, as in lupus, diabetes or rheumatoid arthritis. In the case of autoimmunity, endotoxin is thought to combine with a normal healthy cell to create a novel cell surface configuration that the body then attacks as non-self.

non-physiological electrical currents can create the most diverse reactions outside its immediate environment. Such foci can include dead tissues, scars, foreign bodies, cysts and frequently the chronic inflammation present around all dead teeth. Neural therapy suggests that such electrical currents can fool the body's information processing systems in the same way a computer can be fooled by bad input information. If the body is subject to wrong information it may then not properly regulate itself. For example, dead front teeth often affect the bladder, urogenital area and knees, so that the focal disturbance (the tooth) creates a regulation problem — for example, hormonal imbalance, PMT, menstrual irregularity or perhaps pathology on a physical level.

The mechanism for transmission of the electrical disturbance from the focus to the affected remote site is via acupuncture meridians, the autonomic nervous system and the less understood connection via extracellular fluid. The influence of acupuncture meridians means that frequently the dead or root-filled tooth will have somewhat predictable effects. These can be determined by consulting the acupuncture chart (see Diagram C).

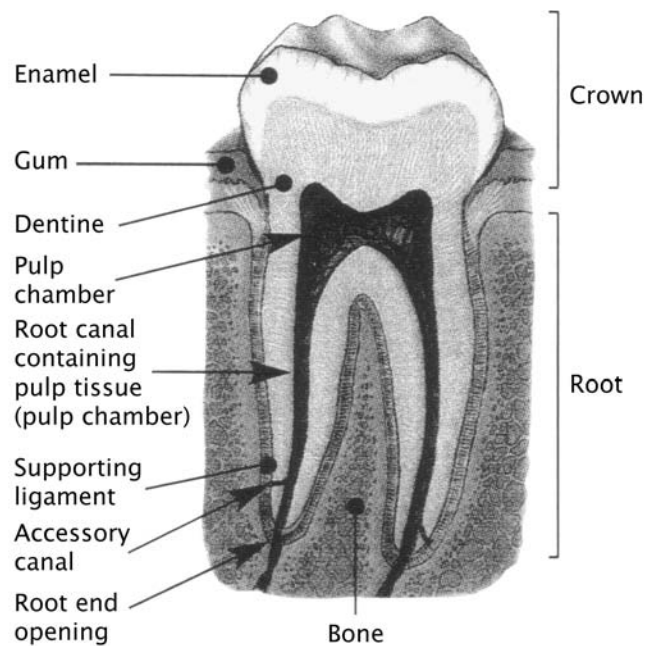


DIAGRAM A

A HEALTHY TOOTH

In case this seems esoteric, it should be noted that focal disturbances are considered to be the underlying cause of one-third of illness. It's also accepted that about 70 per cent of such disturbances are located in the mouth. Perhaps we should not be surprised at this, as no other treatment modality except conventional dentistry routinely leaves dead, infected tissue in place.

**Dr David  
Howard**

**Wholistic approach to  
general and cosmetic  
dentistry.**

Phone. 9436 1211 Fax. 9438 4965  
Suite 102, 2-4 Pacific Highway, St Leonards, 2063

Chart showing relationship between teeth and other areas of the body

SENSE ORGANS	Inner ear	Maxillary sinus	Ethmoid cells	Eye	Frontal sinus	Frontal sinus	Eye	Ethmoid cells	Maxillary sinus	Inner ear								
JOINTS	Shoulder Elbow	Jaws	Shoulder Elbow	Back of knee		Back of knee		Shoulder Elbow	Jaws	Shoulder Elbow								
	Hand ulnar Foot plantar Toes, sacro- iliac joint	Front of knee	Hand radial Foot Big toe	Hip	Sacrococcyx	Sacrococcyx	Hip	Hand radial Foot Big toe	Front of knee	Hand ulnar Foot plantar Toes, sacro- iliac joint								
				Foot		Foot												
SPINAL SEGMENTS	C6 T1 T5 T6 T7 S1 S2 S3	T11 T12 L1	C5 C6 C7 T2 T3 T4 L4 L5	T8 T9 T10	L2 L3 S4 S5 Coccyx	L2 L3 S4 S5 Coccyx	T8 T9 T10	C5 C6 C7 T2 T3 T4 L4 L5	T11 T12 L1	C8 T1 T5 T6 T7 S1 S2 S3								
VERTEBRAE	C7 T1 T5 T6 S1 S2	T11 T12 L1	C5 C6 C7 T3 T4 L4 L5	T9 T10	L2 L3 S3 S4 S5 Coccyx	L2 L3 S3 S4 S5 Coccyx	T9 T10	C5 C6 C7 T3 T4 L4 L5	T11 T12 L1	C7 T1 T5 T6 S1 S2								
ORGANS	Heart rt	Pancreas	Lung rt	Liver rt	Kidney rt	Kidney lt	Liver lt	Lung lt	Spleen	Heart lt								
	Duodenum	Stomach rt	Large intestine rt	Gall-bladder	Bladder rt Urogenital area	Bladder lt Urogenital area	Bile ducts lt	Large intestine lt	Stomach lt	Jejunum ileum lt								
ENDOCRINE GLANDS	Ant. lobe of pituitary	Para-thyroid	Thyroid	Thymus	Post. lobe of pituitary	Pineal gland	Pineal gland	Post. lobe of pituitary	Thymus	Thyroid	Para-thyroid	Ant. lobe of pituitary						
OTHERS	CNS Psyche	Mammary gland rt							Mammary gland lt	CNS Psyche								
OTHERS	R																	L
	Tooth	8	7	6	5 (V)	4 (IV)	3 (III)	2 (II)	1 (I)	1 (I)	2 (II)	3 (III)	4 (IV)	5 (V)	6	7	8	Tooth
	R																	L
OTHERS	Energy metabolism			Mammary gland rt							Mammary gland lt			Energy metabolism				
ENDOCRINE GLDS TISSUE SYSTEMS	Peripheral nerves	Ar- teries	Veins	Lymph vessels	Gonad	Suprarenal gld	Suprarenal gld	Gonad	Lymph vessels	Veins	Ar- teries	Peripheral nervous system						
ORGANS	ileum rt	Large intestine rt ileocecal region	Stomach rt Pylorus	Gall- bladder	Bladder rt Urogenital area	Bladder lt Urogenital area	Bile ducts lt	Stomach lt	Large intestine lt	Jejunum ileum lt								
	Heart rt		Lung rt	Pancreas	Liver rt	Kidney rt	Kidney lt	Liver lt	Spleen	Lung lt	Heart lt							
VERTEBRAE	C7 T1 T5 T6 S1 S2	C5 C6 C7 T3 T4 L4 L5	T11 T12 L1	T9 T10	L2 L3 S3 S4 S5 Coccyx	L2 L3 S3 S4 S5 Coccyx	T9 T10	T11 T12 L1	C5 C6 C7 T3 T4 L4 L5	C7 T1 T5 T6 S1 S2								
SPINAL SEGMENTS	C8 T1 T5 T6 T7 S1 S2 S3	C5 C6 C7 T2 T3 T4 L4 L5	T11 T12 L1	T8 T9 T10	L2 L3 S4 S5 Coccyx	L2 L3 S4 S5 Coccyx	T8 T9 T10	T11 T12 L1	C5 C6 C7 T2 T3 T4 L4 L5	C8 T1 T5 T6 T7 S1 S2 S3								
JOINTS	Shoulder and elbow		Front of knee	Back of knee		Back of knee		Front of knee	Shoulder and elbow									
	Hand ulnar Foot plantar Toes, sacro- iliac joint	Hand radial Foot Big toe	Hip	Sacrococcyx	Sacrococcyx	Hip	Hand ulnar Foot plantar Toes, sacro- iliac joint	Hand radial Foot Big toe	Shoulder and elbow									
			Jaws		Foot					Jaws								
SENSE ORGANS	Ear	Ethmoid cells	Maxillary sinus	Eye	Frontal sinus	Frontal sinus	Eye	Maxillary sinus	Ethmoid cells	Ear								

DIAGRAM C

When focal disturbances are removed, the response is frequently dramatic, often occurring in minutes. In two recent cases, women with a root-filled upper molar had unilateral sinusitis, breast lumps and stomach upsets. In both cases, the problems resolved within days of removing the tooth. One patient reported full neck movement within hours of extraction of the dead tooth, having suffered 12 years of restricted movement.

Most of the community and certainly dentists are educated to try to save teeth at all costs. At first consideration, it seems a big deal to remove a tooth. Perhaps, though, this is a much less significant procedure than undergoing surgery to remote areas (in the abovementioned case to the sinus and breasts) or endless neck treatments.

Not all root-filled and dead teeth are bad for health. Some people, perhaps 20-30 per cent of the population, do cope with such teeth. It's thought that people with a strong genetic inheritance can cope with root-filled teeth. Research has suggested that people with no family history of degenerative diseases — for example, cancer or arthritis — in the previous two generations, including grandparents' siblings, are less likely to be susceptible.

Long-standing research has also shown that many people can cope with root canals up to a point. This point may be an incident such as pregnancy, glandular fever, pneumonia, hepatitis or other stressor that eliminates the margin of health the person had that previously enabled them to cope with the root canal toxins and electrical effects.

## Removal

One of the biggest problems for dentists is that it is scientifically hard to determine which teeth to remove. The University of Kentucky, USA, does a test on the fluid around a dead tooth and samples I have sent usually show that 30 per cent are relatively innocuous. This test is focused on two toxins and does not consider allergenic, endotoxin or neural focal effects. Other tests include applied kinesiology, which works only if the practitioner is skilled in kinesiology and asks the right questions. Electro-acupuncture diagnosis — for example, listen, vega and thermography testing — is also excellent. All tests have mixed reliability and a decision to remove such a tooth often comes down to instinct and patient assessment of information. But it can be very difficult.

I am confident to suggest that if health is important it is best to have dead teeth removed. Tooth extraction involves more than just pulling out the tooth, which on its own can leave you with the same problem. When dead teeth are removed, the ligament attaching the tooth to the bone must be removed with a dental bur, as the toxins, endotoxin and lymphocytes are embedded up to one millimetre in the bone surrounding the tooth. For good healing to occur, these must therefore be removed.

As in most things, prevention is always preferable. We should all practise good dental care to prevent tooth decay in the first place.